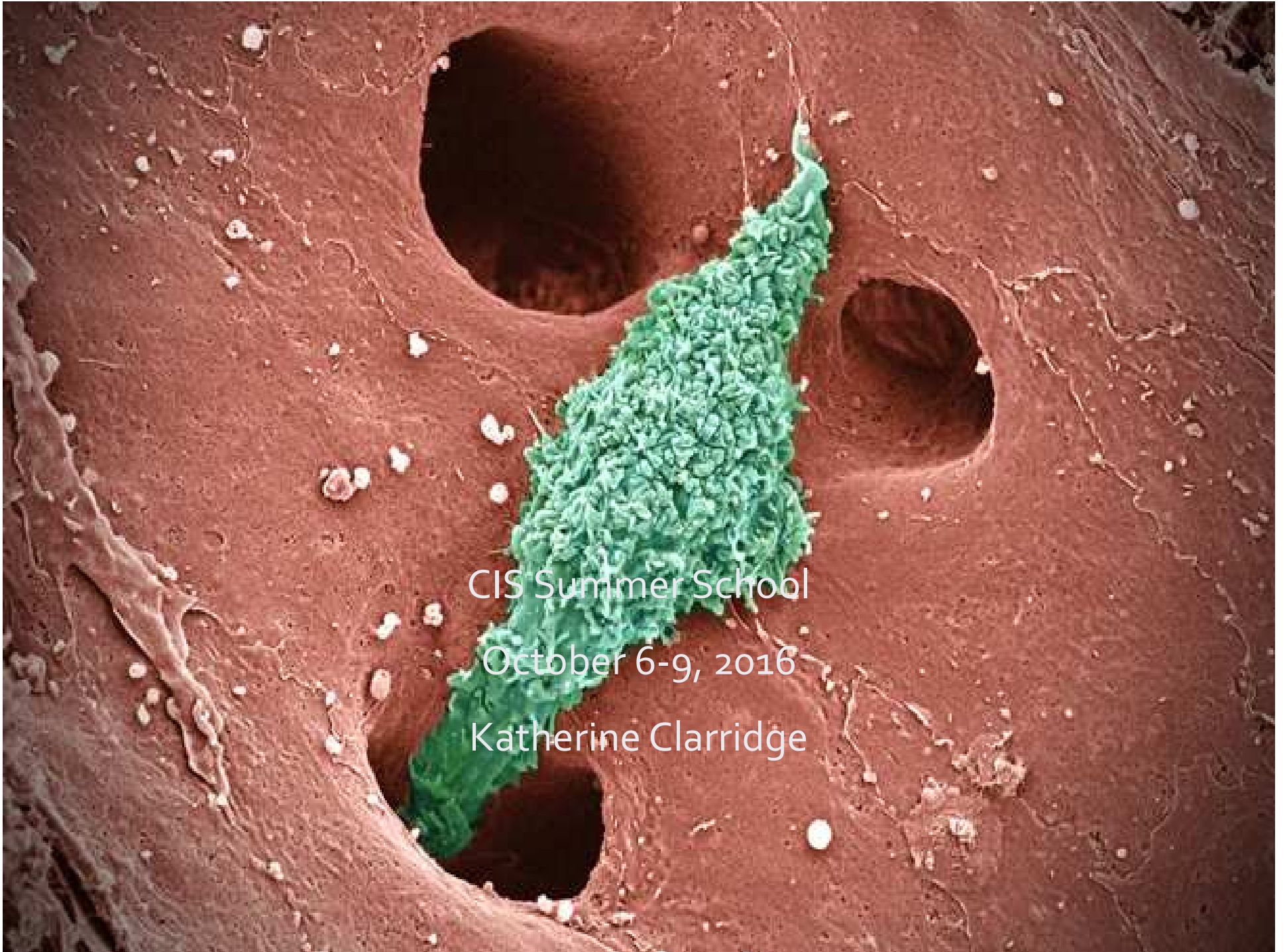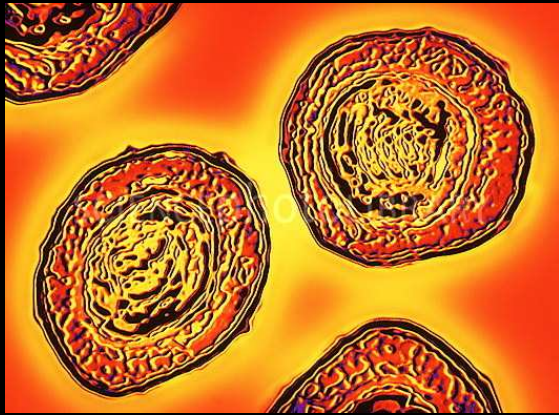




CIS Summer School
October 6-9, 2016
Katherine Clarridge



Presentation

- 20 year old male presents with a history of:
 - Chronic diarrhea for the past several years
 - Osteomyelitis of the right femoral head and ankle
 - Cutaneous involvement
 - Bacteremia
-All with the same organism

Physical Exam

- T 37, HR 85, BP 120/69, RR 18, O₂ sat 100%
- General: alert and oriented
- Oral Cavity: thrush
- Skin: scars on lower extremities from previous surgeries for osteomyelitis and skin infection
- GI: soft, nontender, increased bowel sounds
- Lymph nodes: shotty cervical LAD

Labs

CD3 1054 (72.7)
 CD4 671 (46.3)
 CD8 373 (25.7)
 CD19 155 (10.7)
 NK 229 (15.8)

IgG 1151
 IgA 6
 IgM 158
 IgE 10.7

~~6.67~~ ~~12.1~~ ~~121~~
~~37.5~~

Neutrophils: 4260
 Lymphocytes: 1450
 Monocytes: 440

~~14.2~~ ~~103~~ ~~0.83~~
~~4.4~~ ~~25~~ ~~103~~

CRP: 65
 ESR: 46
 CK: 26
 Alk Phos: 151
 ALT: 17
 AST: 21
 T/D Bili: 0.2/0.2
 Albumin: 3.5

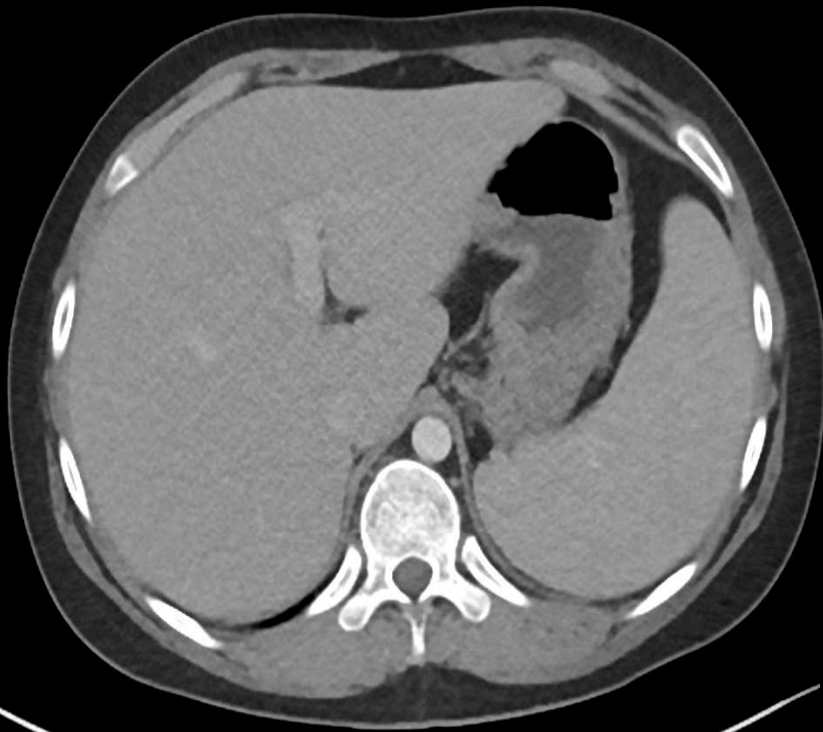
~~14.3~~ ~~1409~~
~~42.2~~

Lipase: 17
 Haptoglobin:

Investigations

- Colonoscopy and endoscopy
 - extensive colitis with nodules and plaques
 - Histology revealed macrophages filled with intracytoplasmic organisms
- Blood and stool cultures
 - *Bordetella hinzii*

Imaging



- Colonic wall thickening
- Enlarged spleen
- Mesenteric lymphadenopathy
- AVN of the right femoral head

